

## Idiopathic Gingival Hyperplasia: a case report

Lalit Patil,<sup>1</sup> Preetam Shah,<sup>2</sup> Priyanka Chopade,<sup>3</sup> Smita Patil,<sup>4</sup> Chandrakant Bangar<sup>5</sup>

### Abstract:

Gingival hyperplasia is a rare condition affecting the patient cosmetically and functionally. In some instances, gingival hyperplasia is drug-induced or may exist as an isolated abnormality or as part of a syndrome. The gingival enlargement causes food excursion, collects food debris and irritating plaque comprising periodontopathic bacteria are believed to prolong and aggravate the disease process resulting in bone loss and root resorption. A case diagnosed clinically and histologically as idiopathic gingival hyperplasia and its management is discussed in this article that includes surgical management of gingival hyperplasia. Patient with gingival hyperplasia should be examined to exclude other reasons to determine the idiopathic gingival fibromatosis or not. The maintenance of treated cases should include meticulous home care and professional recalls. It is important that comprehensive diagnosis, treatment planning and histological examination should be carried out which determine the long-term success of treatment protocol.

**Key words:** gingival enlargement, hyperplasia, fibromatosis, gingivectomy

### Introduction:

Gingivitis is referred to as an inflammatory reaction of the gingiva caused by the bacterial plaque colonization on tooth surfaces and subsequent invasion of microorganisms into the gingival sulcus.<sup>1</sup> Gingival hyperplasia is a rare condition that could be an indication of underlying systemic disease such as uncontrolled diabetes, pregnancy, and puberty where gingival hyperplasia is observed.<sup>2,3,4</sup> Gingival hyperplasia may be associated with the administration of several drugs such as anticonvulsants, calcium channel blockers, and immunosuppressant cyclosporin.<sup>5</sup> Gingival overgrowth occurs in about 50 percent of the persons taking phenytoin.<sup>6</sup> Gingival enlargements are also observed in several blood dyscrasias like acute monocytic, lymphocytic or myelocytic leukemia. Other etiologic factors are enlisted in **Table I**.

Slowly progressive fibrous enlargement of maxillary and mandibular gingiva is a feature of idiopathic gingival hyperplasia. Characteristically, this massive gingival enlargement appears that covers the tooth

surfaces and displaces the teeth, while the cause of the condition is unknown.<sup>7-8</sup> On histological examination, the diseased tissue contains an increased amount of mature collagenous connective tissue and a mild hyperplasia of the overlying epithelium. Gingival fibromatosis may exist as an isolated abnormality or as a part of the syndrome.<sup>9</sup>

### Case Report:

A 7-year-old girl reported to the Department of Pediatric and Preventive Dentistry, Bharati Vidyapeeth Dental College and Hospital, Pune with gradual and progressive enlargement of lower gingival tissue on the lingual side from the age of 6 years, preventing proper speech articulation. The patient did not have any history of fever, prolonged medications, anorexia, weight loss, seizures, or hearing loss or any systemic illness. Family and postnatal history of the patient was non-contributory. The patient did not take any medication that could be associated with gingival hyperplasia. She did not appear to have any mental impairment.

**Table I: Causes of gingival hyperplasia.**

Condition	Sign and Symptoms	Heredity/Cause
Drug-induced gingival overgrowth	Extensive Gingival Overgrowth	Drugs Like Phenytoin, Dilantin
Leukaemia	Enlarged, oedematous, soft and tender, easily bleeding gingivitis	Blood Dyscrasias
Thrombocytopenia and thrombocytopathy	Gingival enlargement and spontaneous bleeding	Blood Dyscrasias
Rutherford Syndrome	Corneal dystrophy	Dominant
Cross Syndrome	Microphthalmia, mental retardation, pigmentary defects	Recessive
Ramon Syndrome	Hypertrichosis, mental retardation, delayed development epilepsy, cherubism	Recessive
Laband Syndrome	Syndactyly, nose and ear abnormalities, hyperplasia of the nails and terminal phalanges	Dominant

On extra-oral examination, no other anomaly was found which was relevant to the condition. The intra-oral examination revealed localized gingival hyperplasia on the lingual aspect of the mandibular arch. The gingival tissue partially covered the crowns of the anterior teeth. It was pink with firm, dense and fibrous consistency. (Figure I). Tongue movements were restricted. Speech trouble was seen which was under the treatment of speech therapist. Gingival tissue did not bleed or show any release of exudates. Complete blood cell count and histopathological examinations were carried out. Hematological investigations were within the normal limits. Histopathological investigations after excisional biopsy showed stratified squamous epithelium which was parakeratinized in nature (Figure II A). It showed thin and long rete ridges with hyperchromatic basal cells (Figure II B). Few chronic inflammatory cells, chiefly lymphocytes were seen. Engorged blood vessels were also seen with extravasated RBCs (Figure II C). With the clinical and the histopathological examinations, the case was diagnosed as idiopathic gingival hyperplasia. Based on the above findings, gingivectomy was performed quadrant-wise from 33-43 under local anesthesia to restore the

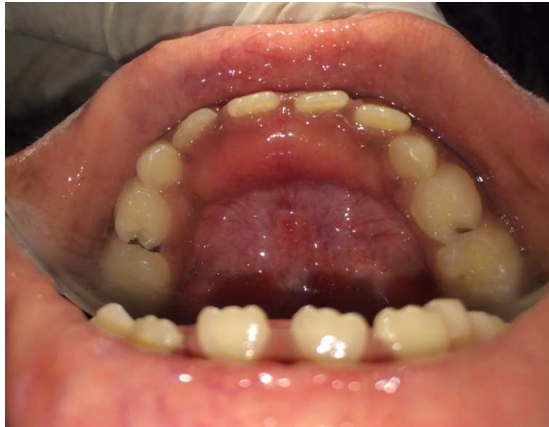functional/ masticatory needs of the patient.

The incision was made distal to 33 -43 (Figure III A). Kirkland knives were used for incisions on the facial, lingual, and cervical surfaces. Orban periodontal knives were used for inter-dental incisions. Full envelope flap was raised, and surgical excision of the gingival overgrowth was carried out (Figure III B). After excision of the gingival tissue, the flap was closed and sutured (Figure IV). A pressure pack was used to control postoperative bleeding. Once the bleeding was under control, a periodontal dressing (COE-PAK, Periodontal Dressing; GC America Inc., ALSIP, IL 60803, US) was given to promote healing. The patient was recalled after 20 days for a checkup (Figure V).

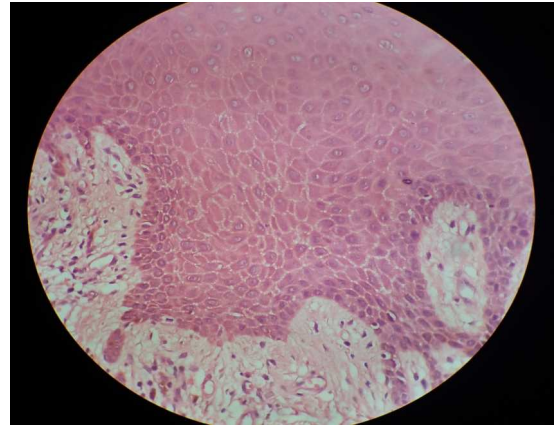
### Discussion:

Gingival fibromatosis is frequently associated with a variety of syndromes.<sup>10</sup> A syndrome associated with hearing deficiencies, hypertelorism and supernumerary teeth has been reported by Wynne et al<sup>11</sup> and Takagi et al.<sup>12</sup> Recently a mutation in the SOS-1 gene has been found that segregates the hereditary gingival fibromatosis phenotype.<sup>13</sup>

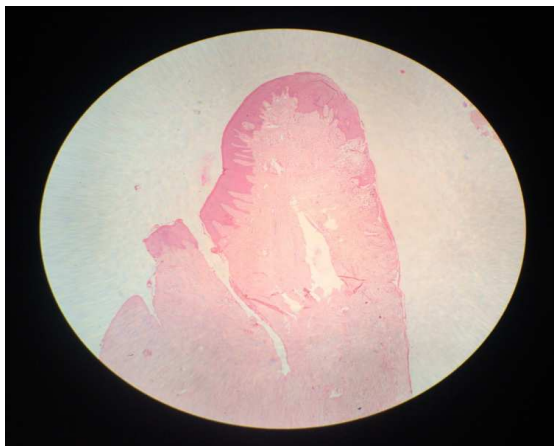
**Figure I: Intraoral photograph showing gingival enlargement**



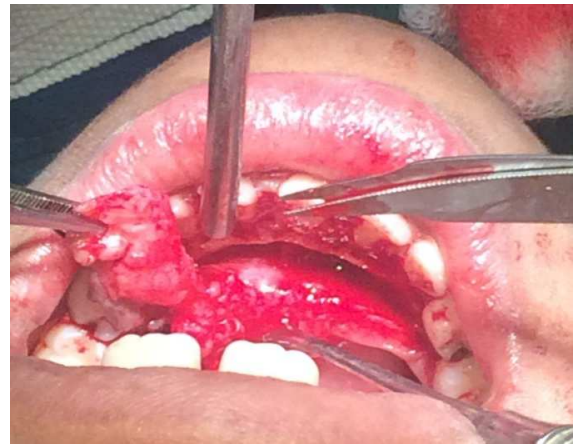**Figure IIC: Engorged blood vessels with extravasated RBCs**



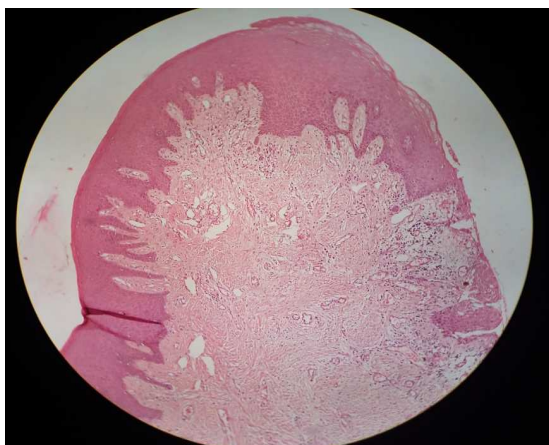**Figure IIA: Histological examination showing parakeratinized stratified squamous epithelium**



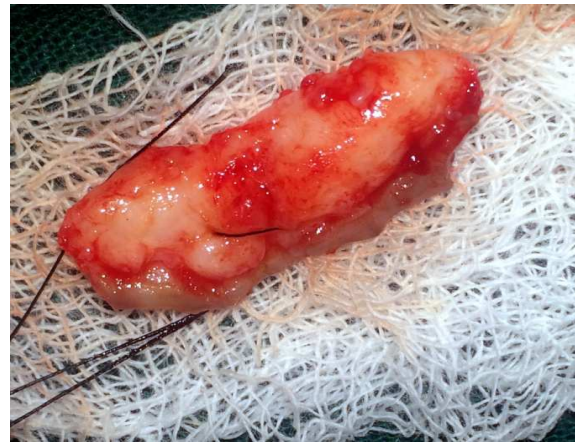
**Figure IIIA: Gingivectomy specimen for histopathological examination**



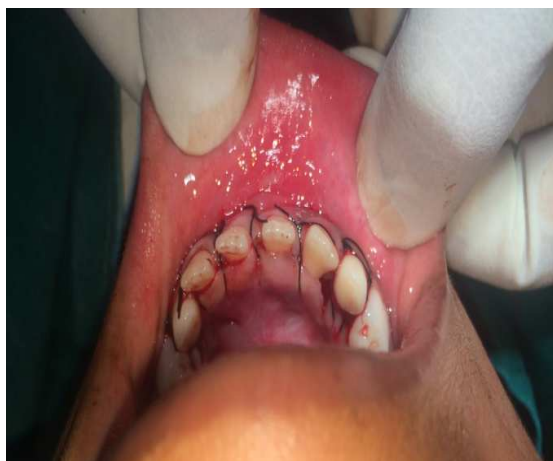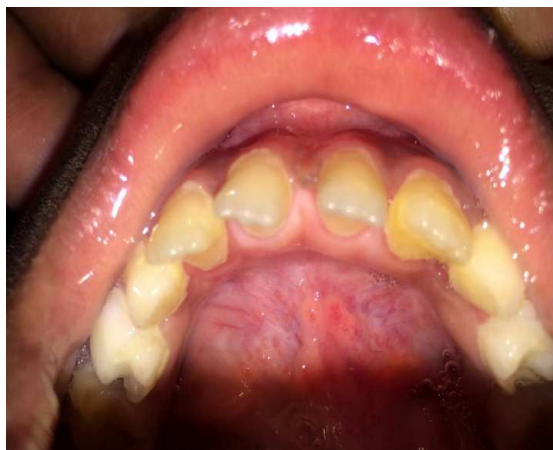**Figure IIB: Thin and long rete ridges with hyperchromatic basal cells**



**Figure IIIB: Gingivectomy specimen for histopathological examination**





**Figure IV: Flap closure****Figure V: Postoperative healing after 20 days**

Our patient had a diagnosis of idiopathic gingival hyperplasia, based on her clinical findings and no history of familial aggregation as well as no clinical features fulfilling any of these possible syndromes. Patients with gingival hyperplasia should be examined carefully and blood samples should be taken to exclude blood dyscrasias. Hematological investigations of our patient were within the normal limits. Gingival enlargement usually begins with the eruption of the permanent dentition but can develop with the eruption of the deciduous dentition; rarely, it may present at birth or arise in adulthood.<sup>14</sup> The age at onset of enlargement is mainly divided into the pre-eruptive period (<6

months), deciduous dentition period (6 months-6 years), mixed dentition period (6-12 years), permanent dentition period before adolescence (12-20 years), and permanent dentition period after adolescence (>20 years).<sup>15</sup> Maximal enlargement occurs either during the loss of deciduous teeth or in the early stages of the eruption of permanent teeth. It progresses rapidly during 'active' eruption and decreases with the end of this stage.<sup>16</sup> In our case, it occurred during the mixed dentition period.

The hyperplastic tissue is usually a normal, pink color. Enlargement may be generalized or localized to specific areas of the mouth, typically the maxillary tuberosities and the labial gingiva around the lower molars. Severity may vary from mild involvement of one quadrant to severe involvement of all four quadrants. A pink color and localized enlargement involving 33-43 were reported in our patient.

There are various procedures available for removal of gingival fibromatosis including surgery, electrocautery, and use of a carbon dioxide laser. If no carbon dioxide laser is available, the most effective method for removing large quantities of gingival tissue, especially when there is no attachment loss and all the pocketing is false, is the conventional, external bevel gingivectomy<sup>17</sup>. Ramer et al<sup>17</sup> advocated quadrant- by- quadrant gingivectomy with periodontal pack placement for one week, followed by 0.2% chlorhexidine oral rinse twice a day for two weeks after each surgery. Based on our findings, gingivectomy was performed quadrant-wise from 33-43 under local anaesthesia to restore the functional/masticatory needs of the patient.

### Conclusions:

The gingival enlargement causes food excursion, collects food debris and irritating plaque comprising periodontopathic bacteria that are believed

to prolong and aggravate the disease process resulting in bone loss and root resorption. The appropriate time for the removal of gingival overgrowth varies. Emerson<sup>18</sup> recommended that the best time should be when all the permanent teeth have erupted. Rushton<sup>19</sup> did not indicate an exact time but suggested that the teeth be free of caries and gingivitis. Patients should be given every opportunity to undergo conservative surgical procedures. The aims are to minimize the displacement of erupting teeth, to reduce malocclusion, and to improve oral function. Improved aesthetics also diminishes psychologic effects in very young patients. The maintenance of treated cases should include meticulous home care and professional recalls.

## References:

1. Shafer WG, Hine MK, Levy BM. A Textbook of Oral Pathology, 4th ed. Philadelphia: WB Saunders; 1983. p.760–800.
2. Katsikeris N, Angelopoulos E, Angelopoulos AP. Peripheral giant cell granuloma: clinicopathological study of 224 new cases and review of 956 reported cases. *Int J Oral and Maxillofac Surg* 1988;17(2): 94–99; [http://dx.doi.org/10.1016/S0901-5027\(88\)80158-99](http://dx.doi.org/10.1016/S0901-5027(88)80158-99)
3. Vally IM, Altini M. Fibromatoses of the oral and paraoral soft tissues and jaws. *Oral Surg Oral Med Oral Pathol Oral Radiol* 1990; 69:191–98; [http://dx.doi.org/10.1016/0030-4220\(90\)90327-O](http://dx.doi.org/10.1016/0030-4220(90)90327-O)
4. Wood NK, Goaz PW. Differential Diagnosis of Oral Lesions, 4th ed. St Louis: CV Mosby; 1991:166.
5. Camargo PM, Melnick PR, Pirih FQM, Lagos R, Takei HH. Treatment of drug-induced gingival enlargement: aesthetic and functional considerations. *Periodontology* 2000; 27:131–38; <http://dx.doi.org/10.1034/j.1600-0757.2001.027001131.x>
6. Hassell TM, Hefti AF. Drug-induced gingival overgrowth: old problem, new problem. *Crit Rev Oral Biol Med* 1991; 2:103–37; <http://dx.doi.org/10.1177/10454411910020010201>
7. Salinas CF. Orofacial findings and genetic disorders. *Birth Defects* 1982; 18: 79–120.
8. Shapiro SD, Jorgenson RJ. Heterogeneity in genetic disorders that affect the orifices. *Birth Defects* 1983; 19(1):155–66.
9. Aldred MJ, Bartold PM. Genetic disorders of the gingivae and periodontium. *Periodontol* 2000; 18: 7–20; <http://dx.doi.org/10.1111/j.1600-0757.1998.tb00135.x>
10. Hart TC, Zhang Y, Gorry MC, Hart PS, Cooper M, Marazita ML, et al.. A mutation in the SOS1 gene causes hereditary gingival fibromatosis type 1. *Am J Hum Genet* 2002; 70(4):943–54; <http://dx.doi.org/10.1086/3396899>
11. Wynne SE, Aldred MJ, Bartold PM. Hereditary gingival fibromatosis with hearing loss and supernumerary teeth—a new syndrome. *J Periodontol* 1995; 66: 75-9. Erratum in: *J Periodontol* 1995; 66:30; <http://dx.doi.org/10.1902/jop.1995.66.1.75>
12. Takagi M, Yamamoto H, Mega H, Hsieh KJ, Shioda S, Enomotos S. Heterogeneity in the gingival fibromatoses. *Cancer* 1991; 68: 2202-12; [http://dx.doi.org/10.1002/1097-0142\(19911115\)68:10<2186](http://dx.doi.org/10.1002/1097-0142(19911115)68:10<2186)
13. Coletta RD, Graner E. Hereditary gingival fibromatosis: a systematic review. *J Periodontol* 2006; 77(5):753–64; <http://dx.doi.org/10.1902/jop.2006.050379>
14. Newman MG, Takei HH, Carranza FA. Carranza's clinical periodontology. 9th ed. Philadelphia: WB Saunders Company; 2002: 285.
15. Anderson J, Cunliffe WJ, Roberts DF, Close H. Hereditary gingival fibromatosis. *Br Med J* 1969; 3:218-9; <http://dx.doi.org/10.1136/bmj.3.5664.218>
16. Fletcher JP. Gingival abnormalities of genetic origin. A preliminary communication with special reference to hereditary generalized gingival fibromatosis. *J Dent Res* 1966; 45:597-612; <http://dx.doi.org/10.1177/00220345660450032401>
17. Ramer M, Marrone J, Stahl B, Burakoff R. Hereditary gingival fibromatosis: identification, treatment, control. *J Am Dent Assoc* 1996; 127:493-5. <http://dx.doi.org/10.14219/jada.archive.1996.0242>

18. Emerson TG. hereditary gingival hyperplasia. Oral Surg Oral Med Oral Pathol 1965; 19:1-4;  
[http://dx.doi.org/10.1016/0030-4220\(65\)90207-0](http://dx.doi.org/10.1016/0030-4220(65)90207-0)

19. Rushton MA. Hereditary or idiopathic hyperplasia of the gums. Dent Practit 1957; 7:136-146.

\*\*\*\*\*

**ACKNOWLEDGEMENTS:** The author wishes to thank the Department of Oral Pathology of Bharati Vidyapeeth Dental College and Hospital, Pune, India, for their guidance.

Conflict of interests: Nil  
Source of funding: Nil

Date of submission: 17-03-2016  
Date of acceptance: 05-04-2016

**Authors details:**

- 1- **Corresponding author:** Post-graduate Student, Department of Pediatric and Preventive Dentistry, Bharati Vidyapeeth Deemed University Dental College and Hospital, Pune- 411001, Maharashtra, India; E-mail: [lalitp673@gmail.com](mailto:lalitp673@gmail.com)
- 2- Professor, Department of Pediatric and Preventive Dentistry, Bharati Vidyapeeth Deemed University Dental College and Hospital, Pune, Maharashtra, India
- 3- Postgraduate Student, Department of Pediatric and Preventive Dentistry, Bharati Vidyapeeth Deemed University Dental College and Hospital, Pune, Maharashtra, India
- 4- Postgraduate Student, Department of Pediatric and Preventive Dentistry, Bharati Vidyapeeth Deemed University Dental College and Hospital, Pune, Maharashtra, India
- 5- Postgraduate student, Department of Orthodontics and Dentofacial Orthopaedics, Saraswati Dhanwantari Dental College and Hospital, Parbhani, Maharashtra, India